Immune mediated disorders (II)

Vesiculobullous Lesions

- Vesicles Are Fluid Filled Blisters, Measures Less Than 5 Mm In Diameter

Vesicle

{

- Bullae Are Many Vesicles Cluster Together And Are More Than 5 Mm In Diameter.

Bulla

Etiology and pathogenesis

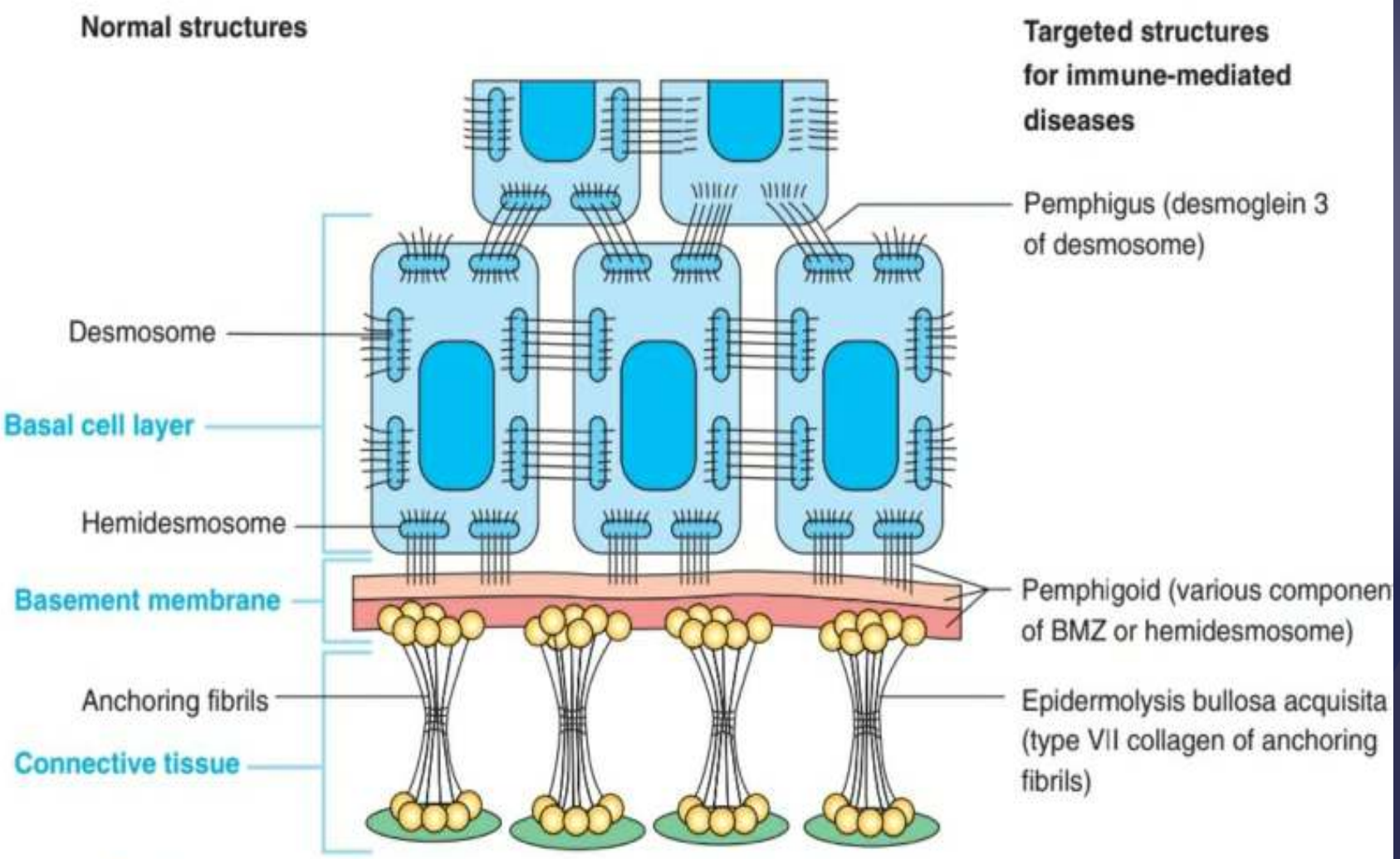

• **Fig. 16-48 Epithelial Attachment Apparatus.** Schematic diagram demonstrating targeted structures in several immune-mediated diseases. *BMZ*, Basement membrane zone.

Pemphigus

- ✔ serious autoimmune mucocutaneous disease characterized by intraepithelial blister formation intial manifestation of PV often involve the oral mucosa , typically in adults, in approximately 60% of cases.
- ✔ oral soreness and examination shows superficial ,ragged erosions and ulcerations distributed haphazardly on the oral mucosa preceded by bullae which vary in size

• **Fig. 16-53 Pemphigus Vulgaris.** This flaccid cutaneous bulla is characteristic of skin involvement.

• **Fig. 16-49 Pemphigus Vulgaris.** Multiple erosions of the left buccal mucosa and soft palate.

• **Fig. 16-51 Pemphigus Vulgaris.** Multiple erosions affecting the marginal gingiva.

• **Fig. 16-50 Pemphigus Vulgaris.** Large, irregularly shaped ulcerations involving the floor of the mouth and ventral tongue.

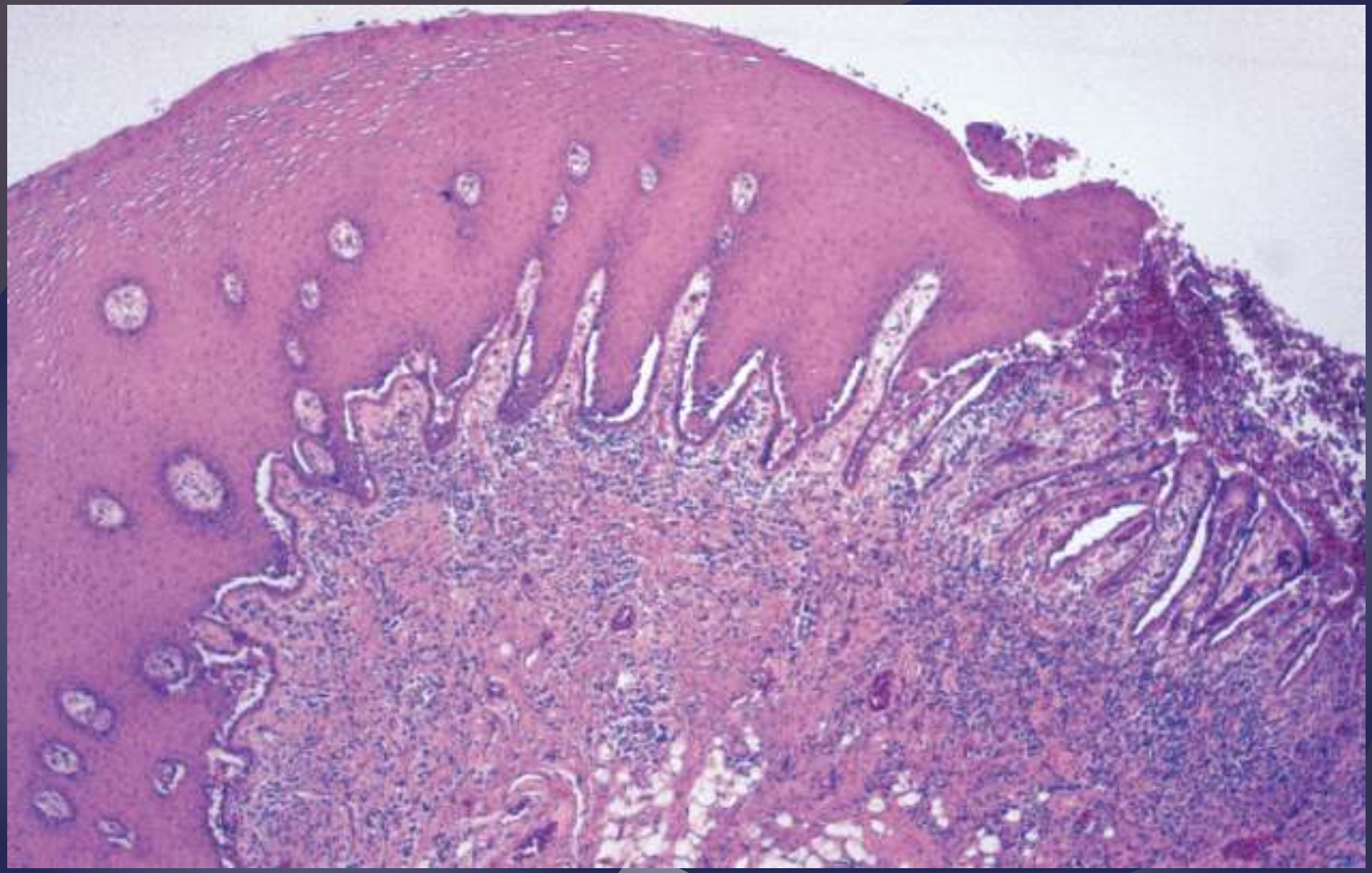

Pemphigus Vulgaris: Low-power photomicrograph of perilesional mucosa. An intraepithelial cleft is located just above the basal cell layer

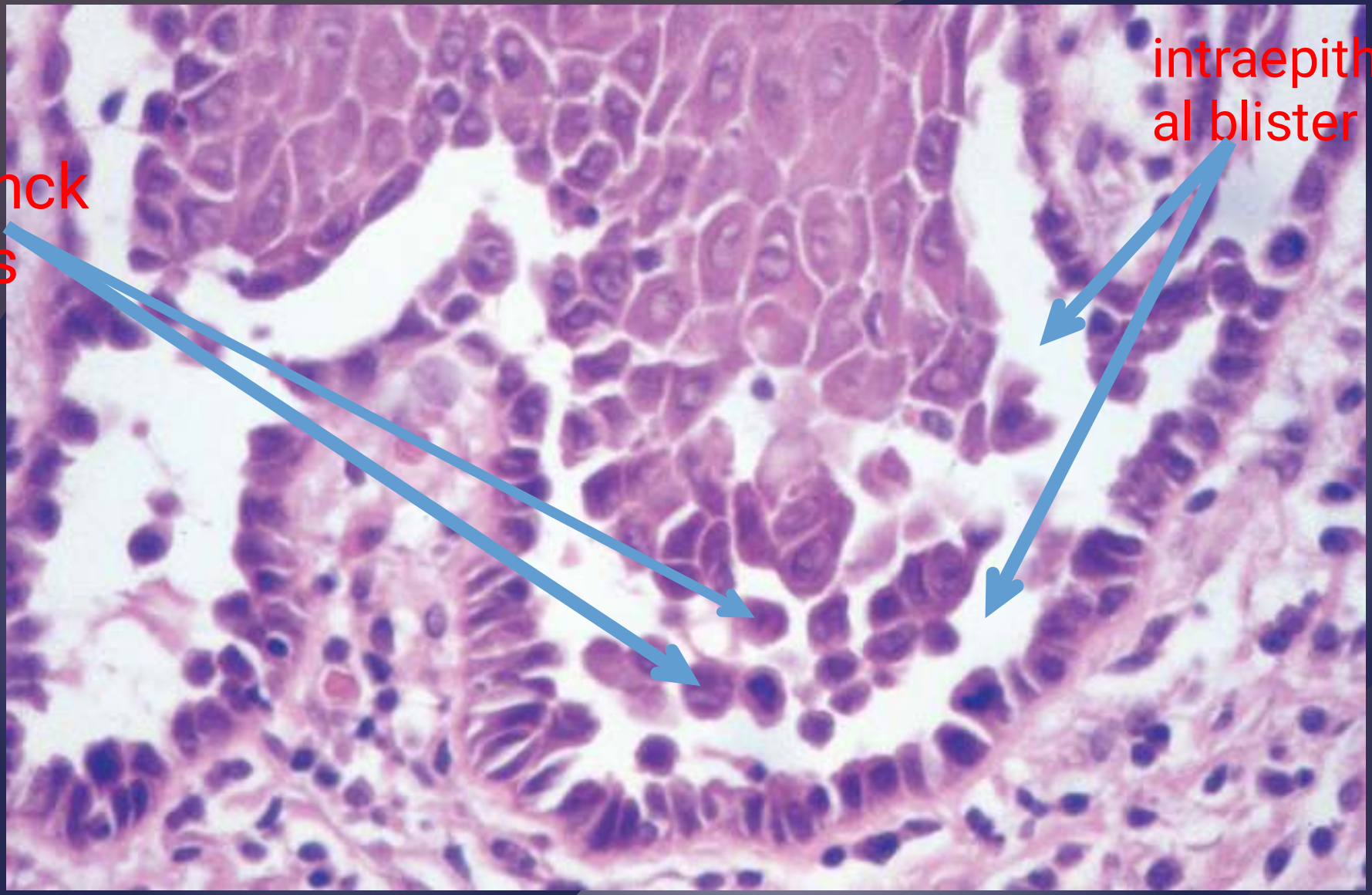

Pemphigus Vulgaris: High-power photomicrograph showing rounded, acantholytic epithelial cells sitting within the intraepithelial cleft.

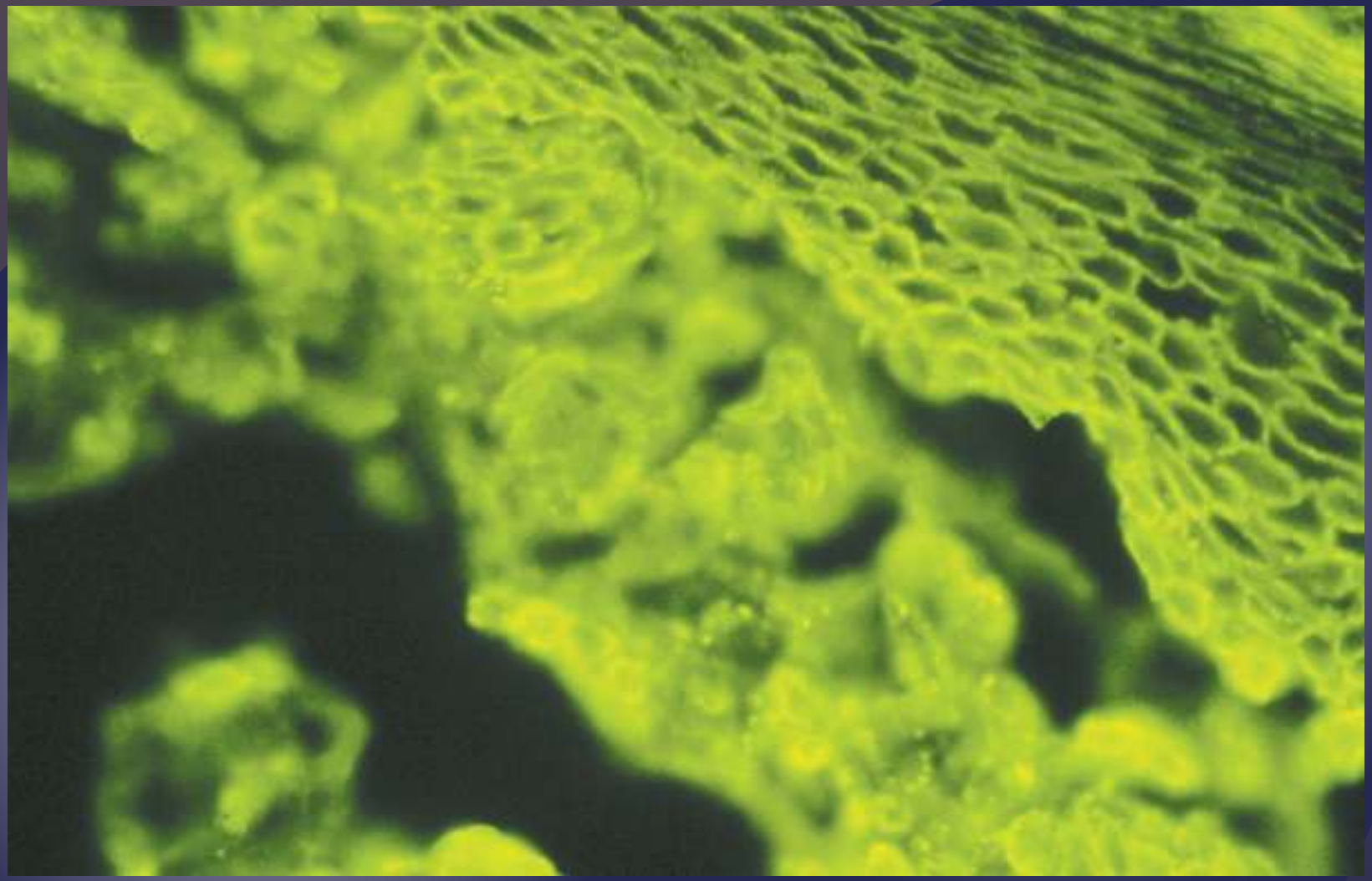

Pemphigus Vulgaris: the direct immunof luorescence pattern. Immunoreactants are deposited in the intercellular areas between the surface epithelial cells, resulting in a “chicken wire” pattern

mucous membrane pemphigoid (Cicatricial Pemphigoid)

- chronic blistering mucocutaneous autoimmune disease tissue-bound autoantibodies are directed against one or more components of the basement membrane.

Although cutaneous lesions are not common, tense bullae such as these may develop on the skin of 20% of affected patients

Mucous Membrane Pemphigoid: One or more intraoral vesicles, as seen on the soft palate. Usually, ulcerations of the oral mucosa are also present

Mucous Membrane Pemphigoid: Large, irregular oral ulcerations characterize the lesions after the initial bullae rupture

Mucous Membrane Pemphigoid: patients with ocular involvement may show adhesions (**symblepharons**) between the bulbar and palpebral conjunctivae before severe ocular damage occurs

Mucous Membrane Pemphigoid: The disease has caused the upper eyelid of this patient to turn inward (**entropion**), resulting in the eyelashes rubbing against the eye itself (**trichiasis**). Also note the obliteration of the lower fornix of the eye

A patient with ocular involvement shows severe conjunctival inf ammation. An ophthalmologist removed the lower eyelashes because of trichiasis associated with entropion.

In this patient, the ocular involvement has resulted in nearly complete scarring between the conjunctival mucosa and the eyelids themselves, producing blindness.

Mucous Membrane Pemphigoid: Often the gingival tissues are the only affected site, resulting in a clinical pattern known as *desquamative gingivitis.* Such a pattern may also be seen with lichen planus and pemphigus vulgaris.

Mucous Membrane Pemphigoid: Medium-power photomicrograph of perilesional tissue shows characteristic subepithelial clefting.

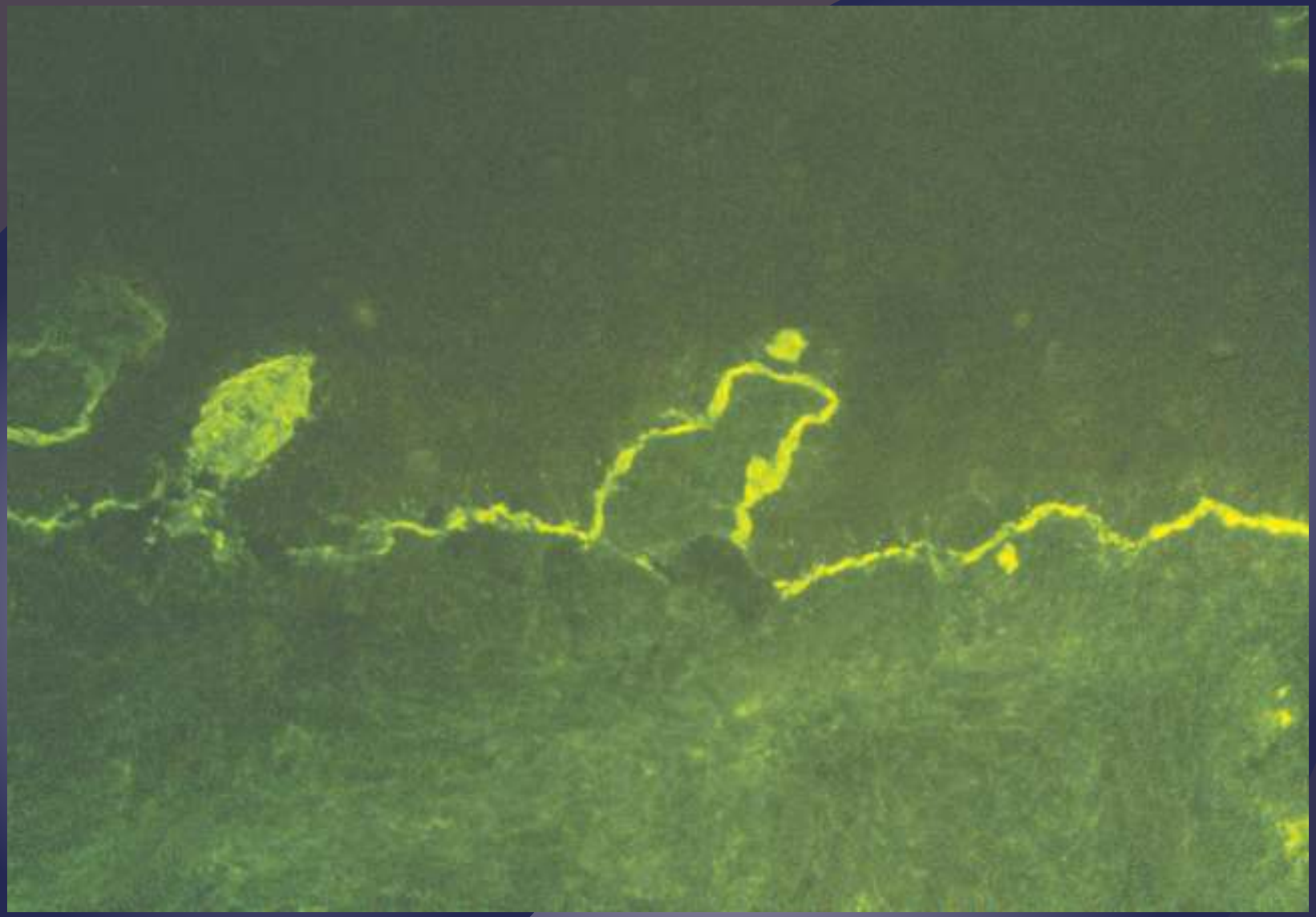

Direct immunof luorescence studies show a deposition of immunoreactants at the basement membrane zone of the epithelium.

Epidermolysis Bullosa

- one acquired and as many as 20 genetic or hereditary varieties (dystrophic, junctional, simplex) that basically are characterized by the formation of blisters at sites of minor trauma.
- Oral lesions are particularly common and severe in the recessive forms
- Oral manifestations include bullae that heal with scar formation, a constricted oral orifice resulting from scar contracture, and hypoplastic teeth.

Epidermolysis Bullosa: A young girl, affected by the dominant dystrophic form, shows the characteristic hemorrhagic bullae, scarring, and erosion associated with minimal trauma to the hands.

Epidermolysis Bullosa: A 19-year-old man, affected by recessive dystrophic form, shows the typical mittenlike deformity of the hand caused by scarring of the tissue after damage associated with normal activity

Epidermolysis Bullosa: A teenaged boy, affected by dominant dystrophic form, shows a reduced depth of the labial vestibule caused by repeated mucosal tearing and healing with scarring.

Epidermolysis Bullosa: Microstomia has been caused by repeated trauma and healing with scarring.

Systemic lupus erythematous

serious multisystem disease with a variety of cutaneous and oral manifestations . In 40% to 50% of affected patients a characteristic rash ,having the pattern of a butterfly develops over the malar area and nose

Systemic Lupus Erythematosus (SLE): This ulceration of the buccal mucosa exhibits f ne radiating white striae at its periphery, clinically appearing similar to erosive lichen planus

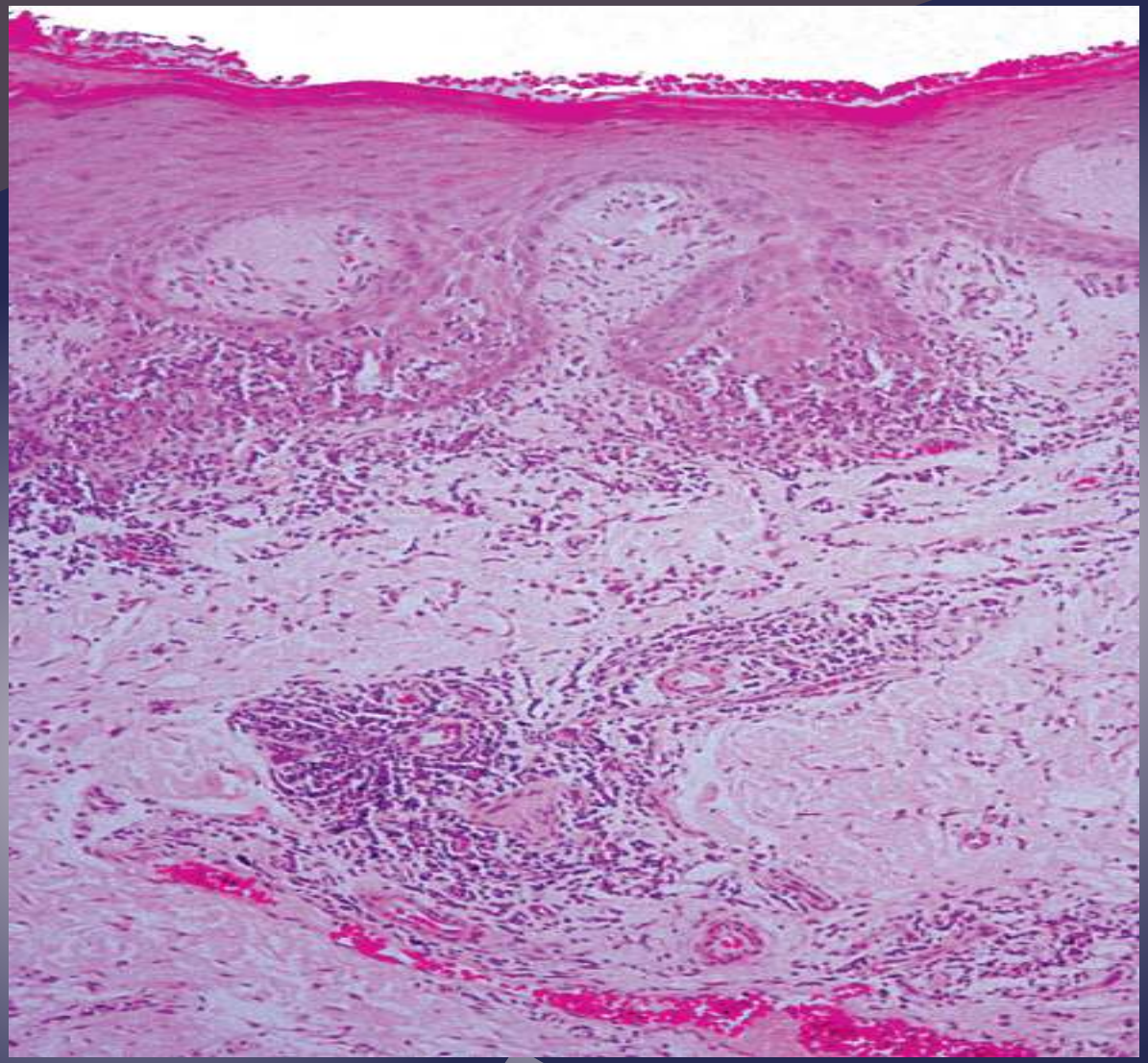

Lupus Erythematosus (LE): Low-power photomicrograph showing hyperparakeratosis with interface mucositis and perivascular inflammation.

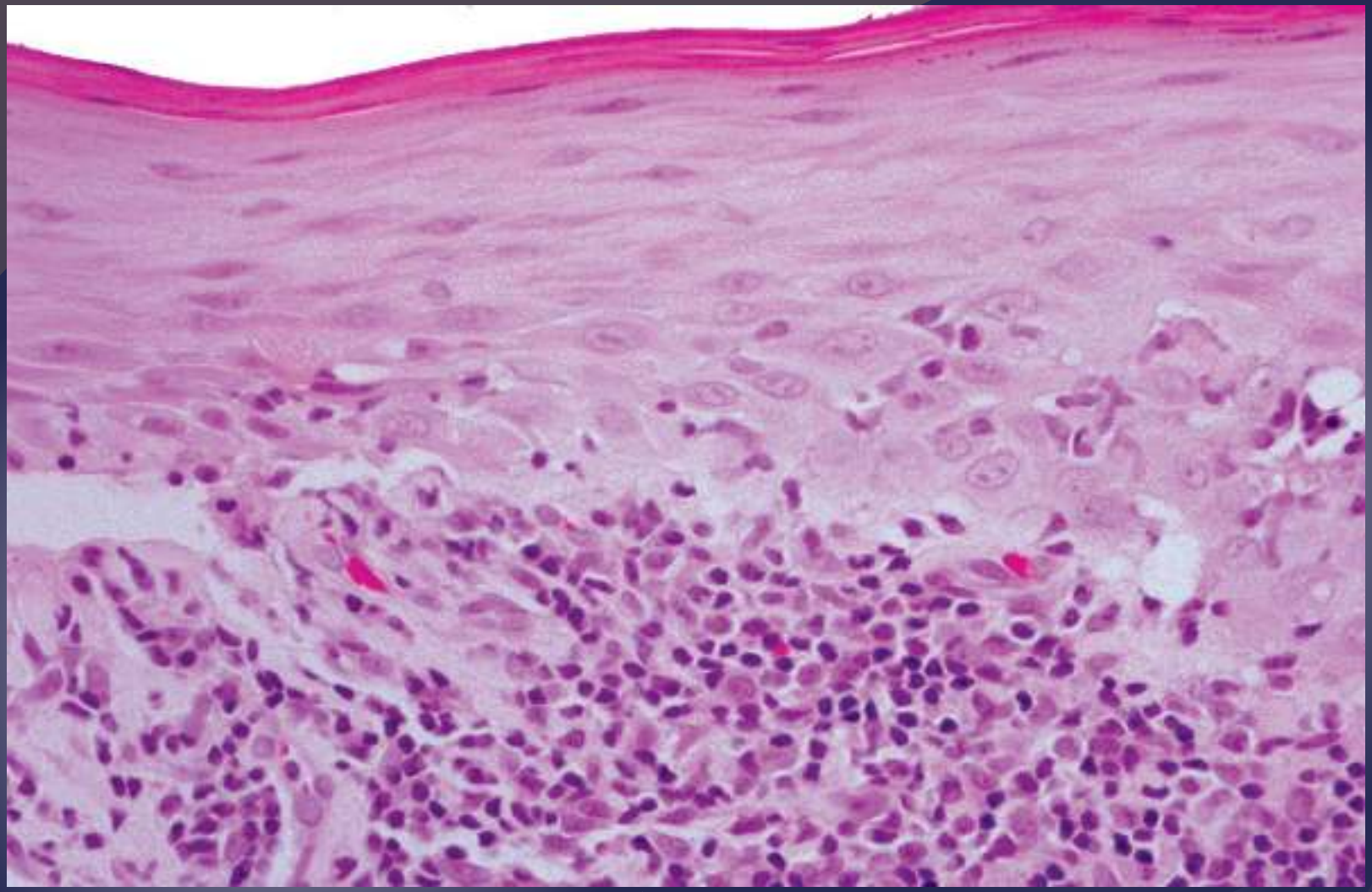

Lupus Erythematosus (LE): High-power photomicrograph of the interface mucositis.

Thank you